

INNOVATIONS IN COSMETIC EYELID SURGERY



Intro

In 2007, there were 240,763 cosmetic eyelid procedures performed in the United States. According to the American Society of Aesthetic Plastic Surgeons, this was the third most common cosmetic surgery performed after liposuction (456,828) and breast augmentation (399,440). Blepharoplasty has become the most commonly performed cosmetic procedure in facial plastic surgery. In this article we will review the history of eyelid surgery, anatomy of periocular aging changes, preoperative and postoperative evaluation and management, surgical complications, revisional eyelid surgery, and some of the most recent advances in cosmetic eyelid surgery.

CE@Home

It has been said that “the eyes are the portal to the soul.” Every time we meet and converse with someone the first thing we notice about them as we make eye contact are their eyes. The anatomical contour and emotional changes of the eyelids and periorbital region play an important role in maintaining facial harmony through expression of human character, mood and feelings. Changes associated with an aging eyelid can project an inaccurate look of fatigue or lack of vitality despite adequate rest and good health.

Blepharoplasty (Greek blepharo = eyelid + plasty = to change or mold) can be performed for functional or aesthetic reasons, or both. Functional blepharoplasty restores normalcy to an eyelid that has been altered by trauma, infection, inflammation, degeneration, neoplasia or developmental errors. Cosmetic surgery attempts to improve the appearance of tissue or structures that are histologically and functionally normal. In either case, the goal of blepharoplasty is the restoration and rejuvenation of the eyes to give a more rested and natural, youthful look.



The goal is to still look like you, just better.

History

The first recorded documentation of blepharoplasty was in the first century AD, when Aulus Cornelius Celsus described the excision of skin for “relaxed upper eyelids” in *De Re Medica*. The term blepharoplasty dates back to 1817, when a German physician Von Graefe described a technique for repairing deformities caused by resection of cancer in the eyelids. In 1907, Conrad Miller wrote *Cosmetic Surgery and the Correction of Featural Imperfections*, the first book of cosmetic surgery. The second edition of this book, published in 1924, contained diagrams of incisions for upper and lower eyelid surgery. From the late 1940’s to even as recent as today, orbital fat removal had been an important part of this procedure. In the past 10 years, a new paradigm has emerged in periocular rejuvenation where advanced customized techniques allow re-establishment of youthful characteristics by relying less on removal of fat and more on restoration. The goal is to still look like you, just better.

Anatomy

A discussion about surgery should start with anatomy. The **skin** around the eyelid is unique in that it is very thin and lacks the normal subcutaneous fat. The **eyelid crease** is formed by extensions of the **levator aponeurosis** toward the skin. Although most Caucasians have an eyelid crease, about 50% of Asians do not have one. This is the most common reason an Asian blepharoplasty is performed. **Orbicularis oculi** is a circumferential muscle immediately underneath the skin that is innervated by the ophthalmic branch of the facial nerve (cranial nerve VII) and is responsible for closing the eyelids. The **septum** is the connective tissue immediately posterior to the orbicularis muscle that keeps the orbital content from herniating. With time and

chronic rubbing of the eyes, the septum weakens and allows herniation of orbital fat, which gives the appearance of “puffiness” or “bags” on the lower and upper eyelids. There are three **fatty compartments** on the lower eyelid known as the medial, central and temporal fat pads. The upper eyelid, in contrast, has two fatty compartments, the medial and the central fat pads. The temporal fat pad is replaced by the **lacrimal gland** in the upper eyelid. The **tarsal plate**, which is made up of dense connective tissue, can be thought of as the backbone of the eyelid. The **medial canthus** and **lateral canthus** play an important role in anchoring the eyelids to the orbital bone medially and temporally. Any weakness in these structures can result in eyelid laxity which can in turn give rise to entropion or ectropion.

What are the changes associated with periocular aging?

Smoking, sun damage, genetics, stretching from swelling, and the wear and tear from chronic rubbing and blinking all contribute to changes around the eyelids as we age.

Skin changes: Around our mid-30s the skin around the eyelid starts to thin and lose its elasticity. Slowly this can result in excess skin in the upper eyelids which will cover the crease. The term **dermatochalasia**, which means excessive loose skin, is used to describe this condition.

Orbicularis oculi: As mentioned previously, this circumferential muscle is responsible for eyelid closure. Stretching of this muscle with time also contributes to the overhanging skin. It is the chronic use of this muscle, combined with squinting and sun damage which result in the static wrinkles we see around the eyes termed “crows feet.” There are two types of wrinkles, static and dynamic. Dynamic wrinkles only appear when we are using that specific muscle. For example, if you were to stand in front of a mirror and actively raise your brows you will see dynamic wrinkles in your forehead from activity of the frontalis muscle. Static wrinkles, on the other hand, are present at all times, even when the muscle is at rest. Botox is a neurotoxin and a paralytic agent that acts by inhibiting the action of those specific muscles and thus temporarily (three to five months) decreases static wrinkles.

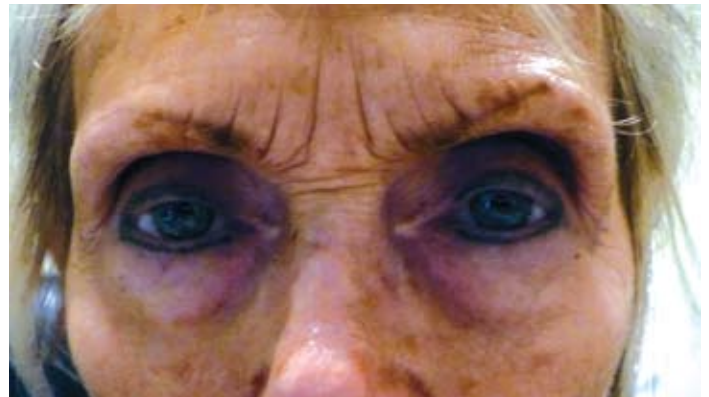
Facial fat and volume: As we age, the facial fat begins to absorb resulting in volume loss in the face. Around the eyes, the loss of midface fat can contribute significantly to the lower eyelid “bags,” and this may be the primary reason they are formed. In the past 10 years most of the modern techniques in periocular rejuvenation take into account this concept of volume loss. Modern techniques in volume replacement include injection of synthetic materials such as Restylane and Juvederm, which are hyaluronic acid products lasting nine to 12 months. An alternative is injection of the patient’s own fat after

a small amount of liposuction; this fat injection lasts a lifetime. It should also be mentioned that soft tissue around the eyes descends with time due to gravity.

Septum: This structure can weaken over time, resulting in herniation of orbital fat and also contributing to the lower eyelid “bags.”

Orbital fat: Not only the orbital fat pockets can herniate through a weakened septum but they too can be partially absorbed and with time give rise to a gaunt and “hollowed” look. Older surgical techniques would remove the excess herniated fat, resulting in a worsening of the “hollowed look.” (Pictured below is a patient who had aggressive fat removal 20 years ago which resulted in the hollowed appearance.) Unfortunately many “old school” surgeons are unwittingly contributing to an epidemic of post-blepharoplasty hollowness.

Figure 1 — A 67 year old female who underwent aggressive blepharoplasty with fat removal 18 years ago. As you can see there is significant post-operative hollowness around the eyes which makes the patient look older and “emaciated.”



Preoperative Evaluation

All new patients should have an initial consultation in which the surgeon listens to understand what is bothering him/her and what it is they would like to achieve. At this time the patient should understand the different surgical options with a realistic expectation of the postoperative outcome.

A full ophthalmic, medical and surgical history should be taken. Attention is paid to any history of dry eyes or ocular disease. Every patient with a history of dry eyes should have a Schirmer’s test performed to assess tear production. However, research has shown the Schirmer’s test to be less important than the history in predicting the development of dry eyes after blepharoplasty. Patients with dry eyes are at risk for worsening of their symptoms and a more conservative surgical treatment is undertaken.

The most important part of the pre-operative exam is an ophthalmic examination including assessment of visual acuity,

extraocular muscle movement, fundoscopic exam, intraocular pressures, tear film adequacy, width of palpebral fissures, and visual fields. An intact Bell's phenomenon is a protective outward and upward rotation of the globe with eyelid closure. The Bell's reflex helps protect against corneal injury and exposure keratopathy. All patients are advised to discontinue use of aspirin and blood thinners 10 days before surgery.

What determines if an upper eyelid blepharoplasty is covered by insurance or Medicare?

The following three criteria are needed by Medicare and most insurance companies to consider an upper eyelid blepharoplasty a medical necessity, known as a functional versus [or rather than] a cosmetic procedure:

1. Documentation by the clinician of the diagnosis of dermatochlasia (excess skin) or ptosis (droopy upper eyelids).
2. Pre-operative photographs of the patient.
3. Documented improvement of more than 12 degrees in superior visual field with the eyelids taped compared to the eyelids untaped.

Upper Eyelid Blepharoplasty

We are as individualized as our fingerprints. Each of us is unique in not only our genetic background but also by exposure to different external environmental factors. Therefore a treatment plan needs to be customized and individualized for that person. Upper eyelid blepharoplasty involves removal of excessive skin or muscle to give a more open vibrant look to the upper eyelids. As mentioned previously excessive orbital fat is almost never removed but rather contoured.

Lower Eyelid Blepharoplasty

This is one procedure that has undergone significant changes in the past 10 years, and because of the delicate structures around this area is the most unforgiving to the untrained hand. The field of oculoplastic surgery has contributed significantly to advances in this procedure. As mentioned previously, most people who want their lower eyelids operated on do so because of "baggy" or "puffy eyelids." Again the reason for the bags is the following:

1. Herniated orbital fat secondary to a weak septum
2. Loss of volume in the midface with aging
3. Excessive skin overhanging

Figure 2 & 3 — Pre-operative and one month post-operative photo of a 36 year old patient who underwent an upper eyelid blepharoplasty. Note the natural post-operative contour. *Actual patient of Dr. Parsa.*

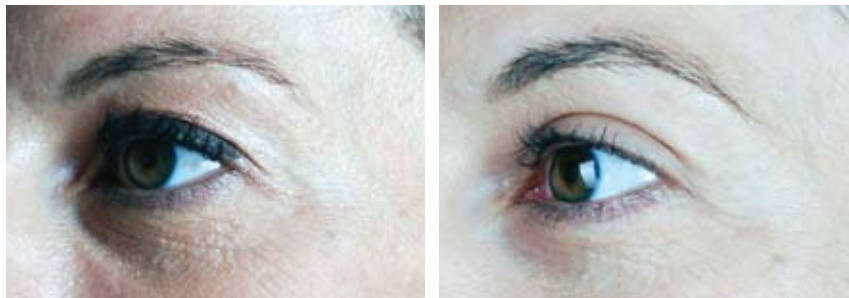
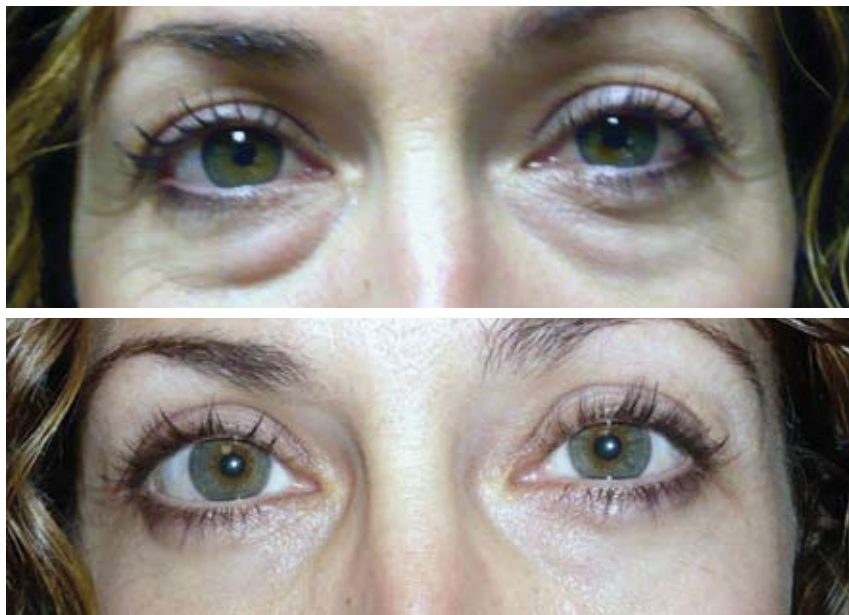
Figure 4 & 5 — Pre- and post-operative view of a patient who underwent an upper and lower eyelid blepharoplasty. *Actual patient of Dr. Parsa.*



During the preoperative exam the contribution of each of these factors is taken into account and an individualized plan is made for the patient.

Fat should almost never be removed from the lower eyelids. Instead, the herniated orbital fat is repositioned back into the orbit and the orbital septum is plicated with sutures to give it strength. Some patients may need a pinch of skin removed from the lower eyelids to give it a tight youthful appearance. Most of the time the midface volume is addressed during the same surgery with autologous fat injection.

We've got the pulse on health insurance...

California Optometric Association members use Marsh to solve health insurance concerns.

Premium rates keep increasing. Benefits keep reducing. It's a never ending rollercoaster. And finding the time to review your options for the upcoming year is usually difficult. COA helps make it easier on you.



Right now you can easily review and compare health insurance coverage that puts your best interests first — with Marsh, the COA-endorsed health insurance consultant.

- **Want to make sure your current plan is still the best for you?** Marsh will review the options available and compare them to your current plan. No risk, no obligation, no pressure to buy.
- **Looking to save money on your coverage?** Marsh will review your current coverage to make sure you're not paying more than you need to — and offer suggestions to help you save money.
- **Tired of increases from your current insurance company?** Marsh works with many insurance carriers so you have access to more alternatives that will work best for you.
- **Wish you had access to HR resources?** Small groups that purchase their health insurance through Marsh are also eligible to enroll in Mercer Select HRKnowHow at no charge. If you need to stay current on health & benefit issues, need sample forms for required compliance tasks such as COBRA, or need at-a-glance information about important HR matters, Mercer Select HRKnowHow may be just what you need.
- **Choice of flexible health insurance solutions:** From HMOs, PPOs to HDHPs and HSAs — we'll find the best solution for you and/or your practice.

Marsh has been serving the needs of optometrists and their practices for more than 10 years. So you can trust them to help you with your health insurance needs — now and in the future.

Marsh is ready to help you today! Call a Client Service Representative at 800-775-2020.

Endorsed by:



Administered by:

MARSH

 MARSH MERCER KROLL
GUY CARPENTER OLIVER WYMAN

DBA in CA: Seabury & Smith Insurance Program Management • CA License #0633005 • 12/08
© 2008 Seabury & Smith Insurance Program Management • 777 South Figueroa Street, Los Angeles, CA 90017 • (800) 775-2020
COA.Insurance@marsh.com • www.MarshAffinity.com

Marsh is part of the family of MMC companies, including Kroll, Guy Carpenter, Mercer, and the Oliver Wyman Group (including Lippincott and NERA Economic Consulting).

Asian Blepharoplasty:

The Asian eyelid is significantly different in anatomy and structure than the occidental eyelid. Approximately 50% of Asians have a defined eyelid crease. This crease divides the upper eyelid into two segments also known as a “double eyelid.” When present, the shape and location of the eyelid crease are lower and different than the occidental eyelid. It must be made clear that most Asian patients without an eyelid crease who seek cosmetic Asian blepharoplasty do not want to look “westernized,” and they do not want to lose their ethnic look.

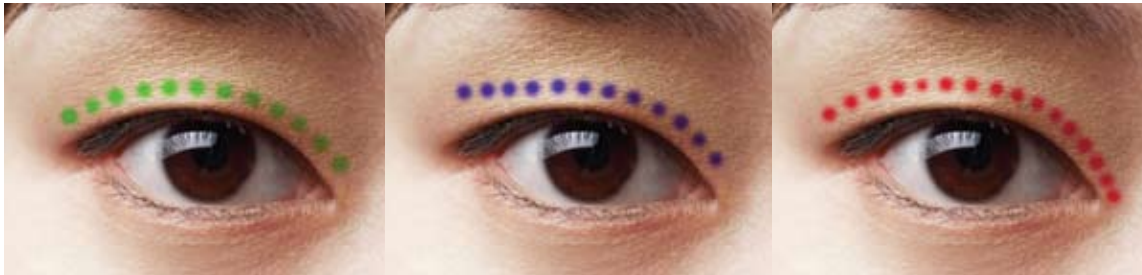Depending on the shape of the face and the patient’s own preferences, various options for the eyelid crease is discussed before the operation. The goal is to create a natural Asian crease rather than a wide open “westernized” occidental crease. Here are some examples of eyelid crease positions.

Figure 6, 7 & 8

Parallel crease

Temporal flare crease

Nasal slant crease



Postoperative Care

Most cosmetic surgery is performed either under local anesthesia or local with IV sedation, otherwise known as “twilight” anesthesia. Bruising and swelling in the first postoperative week is normal. Ice packs are used to reduce swelling for the first 48 hours. Typically most patients are able to return to work or normal activity within one week after surgery. All patients use ophthalmic antibiotic ointment in the postoperative period. Sutures are removed one week after surgery.

Revisional Eyelid Surgery

Revisional surgery is surgical correction of previous poorly performed surgery. Some of the most dreaded complications of facial plastic surgery are those associated with the eyelids. This usually happens when the surgeon is not experienced or familiar with the delicate anatomy around the eyelids. The field of oculoplastic surgery focuses on cosmetic, reconstructive, and revisional surgery around the eyes. It is important to consider this when referring a patient for cosmetic surgery. Depending on the specific problem, the necessary correction may involve a simple procedure or a complex eyelid reconstruction. The goal of revisional surgery is to regain normal function while maintaining aesthetic outcome.

The most common complaint that is referred for revisional surgery is the inability to close the eyes completely after previous cosmetic surgery. This problem usually happens when excess tissue and skin were removed during the previous surgery. Depending on the severity of the case, there are several procedures which can be done or combined to achieve the desired functional and cosmetic outcome. For example,

skin from behind the ear, which very closely matches the texture of eyelid skin can be harvested and used to raise the eyelid. The mid-face can also be elevated by suspension sutures to raise the lower eyelid. The conjunctiva can be elevated by borrowing mucosal tissue from the mouth.

Although subtle, the natural youthful eyelid is V-shaped at the corners. The rounded corners of the eyelids after some cosmetic eyelid surgery is an artificial “operated appearance.” The rounded corners are not only a cosmetic problem for the patient, but they also can interfere with normal blink dynamics. The patient usually complains of tearing or dry eyes. This problem can be reversed by a special surgical technique on an outpatient basis. Postoperative hollowness can be revised by placement or injection of fat into the eyelid or orbit.

Conclusion

The art of oculoplastic surgery has undergone tremendous changes over the years. Today’s modern concepts of beauty and aesthetics rely mostly on minimalism, where less is more. The days of overaggressive procedures have given way to techniques where the focus is mainly on restoration rather than excision.

Dr. Kami Parsa is an oculoplastic and orbital reconstructive surgeon. He is a native of California. After finishing his residency in ophthalmology at USC’s Doheny Eye Institute, he completed a two years fellowship in Oculoplastic Surgery at Bascom Palmer Eye Institute in Miami. He is currently in private practice in Beverly Hills and an attending surgeon at Cedars Sinai Medical Center.

CE Questions

Select the single best answer for the following multiple choice questions:

1. True or False: Blepharoplasty was the 3rd most common cosmetic surgery performed in the United States in 2007.
2. Which muscle is responsible for closing the eyelids?
 - a. Orbicularis oculi
 - b. Levator
 - c. Medial rectus
 - d. Frontalis
3. What is the "backbone of the eyelid"?
 - a. Eyelid crease
 - b. Orbital fat
 - c. Levator
 - d. Tarsal plate
4. Which of the following contribute to changes around the eyelids as we age?
 - a. Chronic eye rubbing
 - b. Genetics
 - c. Sun exposure
 - d. Smoking
 - e. All of the above
5. True or False: Static wrinkles are seen only when using that specific muscle.
6. What is responsible for "bags" under the eye?
 - a. Excessive skin overhanging
 - b. Loss of midface volume
 - c. Herniated orbital fat
 - d. All of the above
7. Which one is not a criterion for Medicare and most insurance companies in the coverage of upper eyelid blepharoplasty?
 - a. Pre-operative photos
 - b. Presence of dry eye
 - c. Diagnosis of dermatochalasis or ptosis
 - d. Documented improvement of 12 degrees in superior visual field with tape vs. no tape
8. Which of the following statements is false?
 - a. Asian blepharoplasty involves creation of an eyelid crease.
 - b. The eyelid crease is formed by extension of the levator aponeurosis to the skin.
 - c. Botox is used as a filler to augment facial volume loss.
 - d. Oculoplastic surgeons specialize in cosmetic, revisional and reconstructive surgery of the eyes and orbit.
9. Which of the following statements is true?
 - a. All orbital fat should be removed during upper eyelid blepharoplasty.
 - b. Revisional surgery can be performed by harvesting graft tissue from the skin, mucous membrane of the mouth, or fat.
 - c. A youthful eyelid is U-shaped at the corners.
 - d. Restylane is a neuroparalytic agent.
10. True or False: Revisional eyelid surgery should be considered if patients are unable to close their eyes after previous cosmetic surgery.

COA Members: No Charge/Non-Members: \$30
 One Hour CE Credit. The deadline for receipt of answers is **May 15, 2009**. Send your answers with your license number to:

COA — Education Coordinator
 PO Box 2591, Sacramento, CA 95812
 Fax: (916) 448-1423 Email: education@coavision.org

Transcripts will be mailed out after the submission deadline.

CE@Home march/april 2009 issue

Name: _____

License Number: _____